

## Computer Aided facial reconstruction of Mary-Magdalene relics following hair and skull analyses

P. Charlier, P. Froesch, N. Benmoussa, A. Augias, Y. Ubelmann, R. Weil, S.  
Morin, F. Straub, Deo Saudamini, Saudamini Deo

► **To cite this version:**

P. Charlier, P. Froesch, N. Benmoussa, A. Augias, Y. Ubelmann, et al.. Computer Aided facial reconstruction of Mary-Magdalene relics following hair and skull analyses. *Clinical Medicine Insights: Ear, Nose and Throat*, SAGE Publications, 2019, 12, pp.1-7. 10.1177/1179550618821933 . hal-02263987

**HAL Id: hal-02263987**


**<https://hal.archives-ouvertes.fr/hal-02263987>**

Submitted on 6 Aug 2019

**HAL** is a multi-disciplinary open access archive for the deposit and dissemination of scientific research documents, whether they are published or not. The documents may come from teaching and research institutions in France or abroad, or from public or private research centers.

L'archive ouverte pluridisciplinaire **HAL**, est destinée au dépôt et à la diffusion de documents scientifiques de niveau recherche, publiés ou non, émanant des établissements d'enseignement et de recherche français ou étrangers, des laboratoires publics ou privés.

# Computer-Aided Facial Reconstruction of “Mary-Magdalene” Relics Following Hair and Skull Analyses

Philippe Charlier<sup>1,2</sup> , Philippe Froesch<sup>2,3</sup>, Nadia Benmoussa<sup>2</sup>, Stéphane Morin<sup>4</sup>, Anaïs Augias<sup>2</sup>, Yves Ubelmann<sup>5</sup>, Raphaël Weil<sup>6</sup>, Soizic Morin<sup>7</sup>, François Straub<sup>8</sup> and Saudamini Deo<sup>2</sup>

<sup>1</sup>Museum of Quai Branly – Jacques Chirac, Paris, France. <sup>2</sup>UVSQ (DANTE Laboratory EA 4498), UFR of Health Sciences, Montigny-Le-Bretonneux, France. <sup>3</sup>VISUALFORENSIC, Strasbourg, France. <sup>4</sup>Bishopric Archives, Bishopric of Fréjus-Toulon, Toulon, France. <sup>5</sup>Iconem, Paris, France. <sup>6</sup>Laboratoire de Physique des Solides, CNRS, Université Paris-Sud, Université Paris-Saclay, Orsay, France. <sup>7</sup>Irstea, UR EABX, Cestas, France. <sup>8</sup>PhycoEco, La Chau-de-Fonds, Switzerland.

Clinical Medicine Insights:  
Ear, Nose and Throat  
Volume 12: 1–7  
© The Author(s) 2019  
Article reuse guidelines:  
sagepub.com/journals-permissions  
DOI: 10.1177/1179550618821933



**ABSTRACT:** The supposed relics of “Mary-Magdalene” are preserved in Provence (France) in an ancient tradition. They consist of a dry skull and a lock of hair. For the first time, they were officially subjected to an extensive medico-surgical examination by photogrammetry, high-magnification binocular lenses, scanning electron microscope, and energy-dispersive X-ray elemental analysis, to propose a full computer-aided facial reconstruction. The preliminary results are presented here.

**KEYWORDS:** Forensic anthropology, anatomy, hair, microscope, photogrammetry, elementary analysis, historical figure

**RECEIVED:** December 4, 2018. **ACCEPTED:** December 7, 2018.

**TYPE:** Original Research

**FUNDING:** The author(s) declared no potential conflicts of interest with respect to the research, authorship, and/or publication of this article.

**DECLARATION OF CONFLICTING INTERESTS:** The author(s) declared the following potential conflicts of interest with respect to the research, authorship, and/or publication of this

article: A preliminary report of this study has been presented to the 7th International Congress of Pathography (Martignes, France, September 2017) and published in *National Geographic* (<https://news.nationalgeographic.com/2017/09/mary-magdalene-face-skull-france-video-spd/>, accessed November 20, 2018). All images remain the property of the authors.

**CORRESPONDING AUTHOR:** Philippe Charlier, Museum of Quai Branly – Jacques Chirac, 222 Rue de l'Université, 75007 Paris, France.  
Email: philippe.charlier@uvsq.fr

## Introduction

In the context of the inventory and systematic examination of the relics preserved in the diocese of Fréjus-Toulon (Provence, southern France), it was possible to conduct the forensic study of the skull and hair (formerly adherent to the skull), constituting the relics known as “of Mary-Magdalene.” This study is the first step in the interdisciplinary study of these important remains for the Christian community (the third most important tomb of all Christianity after the Holy Sepulchre in Jerusalem and the grave of St. Peter in Rome).

## Local Tradition and History

According to a Provençal legend, Mary-Magdalene, Marthe, and Lazarus, their brothers, accompanied by Maximin, Sidoine, Mary Jacobe, Mary Salome, and Sarah, fled from persecution and it was on the coasts of Provence (South-East France) that they were evangelized. Mary-Magdalene then retired for 30 years in the mountains of Sainte-Baume to do penance. Apprehending her approaching death, she finally joined Maximin, who had become bishop of Aix. Maximin then had her buried in the place where the Benedictine priory church (dedicated to this saint) was erected in 1279.

By the 13th century, the exact location of the tomb of Mary-Magdalene had been forgotten. At the time of the Saracen invasions, the body of the saint was supposed to have been transferred to the abbey of Vézelay (Burgundy, France). However, in 1267, the Burgundian monks solemnly presented

the relics they possessed, and it turned out to be a few bones and not the whole body as had been believed until then. It was therefore necessary to seek the latter in Provence, where the Vezelians had supposedly gone to retrieve them. It was Charles II of Salerno, lieutenant of Provence for his father, Count Charles d'Anjou, who, after consulting the local annals and chronicles, undertook excavations in the church of Saint-Maximin where he discovered in December 1279 the crypt sheltering the supposed tomb of Mary-Magdalene.

The contents of the tomb were not examined immediately, but a few days later, in the presence of the bishops of the county of Provence, a whole body was discovered, except the lower jaw and a leg. There was also hair surrounding the skull. Official reports were drafted on the spot by the authorities, direct witnesses of the discovery, and then transferred to the reliquaries (1281–1283). Having succeeded his father in 1285, Charles II presented the head of the saint to Boniface VIII in 1294. The Pope, knowing that the Lateran possessed the supposed jaw of Mary-Magdalene, brought it. As it fit perfectly to the skull, Boniface VIII gave it to the prince. The following year, the Pope granted 6 bulls establishing the Dominicans as guardians of the relics of Mary-Magdalene at Saint-Maximin and at Sainte-Baume, recognizing the feast of the translation of the relics and granting benefits to the pilgrims who would visit “the church of Saint-Maximin, where the body of Saint Mary-Magdalene rests.” These relics and sanctuaries were recognized by the successive Popes.



During the 16th to 18th centuries, relics were periodically recognized and inventoried, usually in the presence of physicians. The relics were desecrated in 1793 but a record of the authenticity of the relics saved from the Revolution was drawn up in 1803. The record, in particular, mentions the head, a bone of the arm, part of Mary-Magdalene's hair, and *Noli me Tangere* (ie, part of dried flesh supposedly touched by the Christ, which remained attached to the skull of the saint until the end of the 18th century). The present reliquary preserving the skull and the *Noli me Tangere* dates from 1860.

The authenticity of the relics was first challenged in the 17th century by Jean de Launoy, followed later by Bishop Louis Duchesne (1843-1922) and Bishop Victor Saxer (1918-2004). It is worth noting that the version of the story of Mary-Magdalene given above is based on the one written by Jacques de Voragine in the *Golden Legend*, dating somewhere between 1261 and 1266: the arrival of Mary-Magdalene in France, her life of penitence in a cave, and her death in Provence. The authenticity of the description in this medieval book is highly contested by many historians of Christianity.<sup>1-4</sup> The origin of this legend may partly have come from confusing or amalgamating many historical characters described in the Gospels and Holy texts during the development of the Roman Catholic Church. Notably, the Pope Gregory I (the Great) fused together the characters of Mary of Magdala, Mary of Bethany (sister of Lazarus), and the unnamed "sinful" woman described in Luke's Gospel. According to the eastern Orthodox Churches, Mary-Magdalene died in Asia Minor, as related by the French bishop and historian Gregory of Tours who wrote (at the end of the 6th century) that the Saint was buried in the city of Ephesus.

In 1974, an anthropological expertise of bones of Mary-Magdalene was entrusted to the CNRS (French National Center for Scientific Research).<sup>5</sup> These bones came from the crypt of Saint-Maximin, the cave of Sainte-Baume, and the reliquary of Magdalene church in Paris. The scientists could not confirm that bones were indeed of Mary-Magdalene, but made anthropological conclusions compatible with this identification. In February 2015, based on 2 pictures taken by a smartphone of this same skull, a Brazilian research team also proposed a "scientific facial reconstruction."<sup>6</sup>

Despite inconclusive evidence about Mary-Magdalene and her life, we wanted to give a face to the famed Saint-Maximin skull. It is in this context that Bishop Dominique Rey, guardian of the relics of his diocese, wished that an interdisciplinary study be conducted, the first scientific results of which are presented here.

## Material and Methods

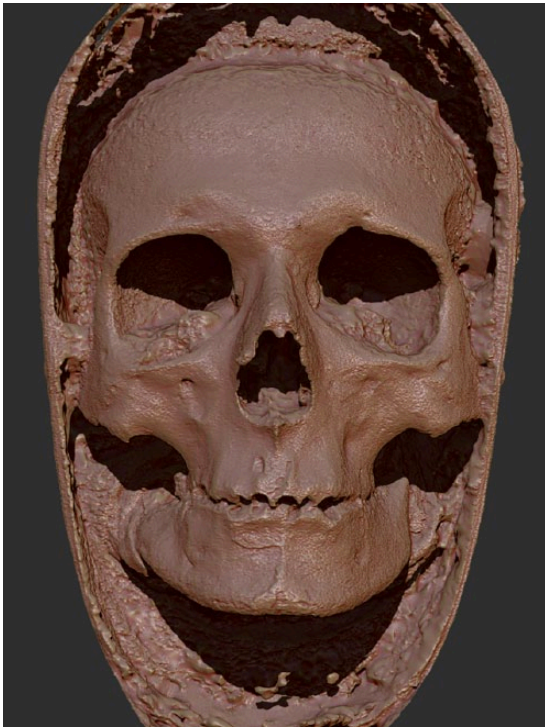For practical and conservative reasons, it was not possible to remove the skull from the voluminous 19th century metallic reliquary located in the crypt of the basilica of Saint-Maximin (Figure 1). Consequently, a photographic survey (nearly 400 photographs) was conducted. All the photographs were taken



**Figure 1.** General view of the skull conserved in the reliquary.

in high definition (HD, 2MB minimum per shot) with a Nikon digital camera, on a fixed stand, with a zenith shift of 1° per photo. All areas of glare were excluded to avoid positional artifacts. All the photographs were indexed by computer system, to get a 3-dimensional (3D) reconstruction by photogrammetry (Figure 2): the 400 images were processed with CapturingReality software, in a Xeon CPU E5 2687W. This software uses an SFM (structure from motion) algorithm able to turn a bunch of pictures into 3D mesh of the skull. The protocol of photo-shooting assures a large overlap between the pictures to ensure that no geometrical distortion is present during the 3D reconstruction process. The output is a mesh (3D surface composed of triangles) with a texture composed of the pixels of images used for reconstruction. From this virtual double of the surface of the skull (accurate to the millimeter), it was possible to perform an anthropological and medico-legal examination.

At the same time, a strand of hair formerly adherent to areas of skin (scalp) of the same skull (Figure 3) was examined under binocular lenses (Leica EZ4 HD; magnification  $\times 2$  to  $\times 40$ ) and a scanning electron microscope (SEM; Field Emission Gun Scanning Electron Microscope; Zeiss Supra55VP). High-resolution observations were obtained by an Everhart-Thornley SE detector at 0.8 or 1.2 kV) followed by microchemical analysis at 15 kV (with an energy-dispersive X-ray=EDX spectrometer Bruker SDD detector mounted on the microscope), and a helium ion microscope (HIM; Zeiss Orion NanoFab; acceleration voltage 30 kV,



**Figure 2.** The 3-dimensional reconstruction of the skull surface using photogrammetry technology.



**Figure 3.** General view of the reliquary containing hair previously adherent to the dry skull.

positive helium ions neutralized by an electron gun near the surface to avoid charging effects). More than 50 microphotographs of the diatoms found on the hair were taken at a  $\times 1000$  to  $\times 42000$  magnification and identified following reference publications using morphologic characteristics (form, size, indentations, etc).<sup>5</sup>

From the virtual double of the surface of the skull (face including the mandible), anthropological data, and information on the morphology of the hair, it was possible to proceed with a facial reconstruction. The objectivity of the reconstruction was assured by the application of a series of verified forensic steps. Blind tests were conducted under scientific control on several key points like prediction of the nose from the skull and resulted positive. Prediction of nasal morphology from the

skull using the Rynn/Wilkinson/Peters method and Gerasimov/Lebedinskaya method, an anthropometric facial reconstruction method based on cylinders and soft tissues depth landmarks (so-called “American method”) and 3D muscles relocation (so-called Russian anatomical method), taking into account the latest updates and the latest technological advances.<sup>7–16</sup>

The bony structure is the key to the facial volume, and the cylindrical depth markers only propose a mean range for the soft tissues that can go from obese to slim. The difference between them only affects the inferior part of the face, cheeks, and neck. The superior part, eyelids, nose, and frontal structure are not affected visually. The subjective part of the work, such as the facial expression, the lighting, and framing of the scene, was done keeping an ethical point of view (no dramatization).

The data collected from the 400 stills taken from the frontal part of the replica were treated by a software that created a digital double in .obj format. The data were composed of millions of polygons (triangles being polygons). We treated the data to reduce the count of poly units down to 100 000 without altering the topography inside ZBrush (Pixologic, Inc., Los Angeles, CA, USA). Reduction in polygons was done by software calculation within ZBrush software using a plugin called Decimation Master that allows to greatly reduce the poly count of a model while preserving the high-resolution details.

Considering preliminary anthropological data confirming a Mediterranean origin, the depth information for the soft tissues markers was inspired by recent orthodontic/cephalometric studies from this geographical region.<sup>17,18</sup> As only some locations (basic lip and chin thickness for women aged 20) were useful in this publication, we decided to mix those data with a complete soft tissues depth list for a 50-year-old white woman, compensating the aging and sagging of tissues. In total, 10 depth markers with the corresponding length were positioned on the sagittal axis and 9 on each lateral part of the face with the Cinema 4D software (Maxon, Friedrichsdorf, Germany; Tables 1 and 2). Those cylinders gave us the probable location of the contour of the skin.

Eyeballs are approximately 24.2 mm in diameter for healthy adults.<sup>19</sup> They are placed centered in the orbits<sup>20</sup>; in lateral view, the iris plane is tangent to an axis touching the superior and inferior orbit ridges.<sup>21</sup> The eyelids were inserted by attaching the palpebral ligament of the external canthus to the malar tubercle zone or 9 mm under the frontozygomatic suture, and the internal ligament is connected to the lacrimal crest zone.<sup>22</sup> The palpebral fissure represents 65% to 70% of the orbit width. The palpebral foil is positioned in an axis replicating the superior orbit ridge direction.<sup>23</sup> The eyelid aperture represents 70% maximum of the orbit width. Nasal reconstruction is done by employing various methods such as the Gerasimov “two tangents”<sup>24,25</sup> modified by Rynn/Wilkinson.<sup>26</sup> Those results gave us a clear indication of the volume. A craniometric method based on regressive equations<sup>27</sup> gave us the correct frontal position and height of the cartilages. We measured 3 distances,  $Nasion > Subspinale = Z$  (60.46 mm),  $Nasion > Acanthion = X$

**Table 1.** Depth markers (in millimeters) on sagittal axis for the “Mary-Magdalene” skull.


Metopion	4.7
Glabella	6.0
Nasion	6.5
Rhinion	2.3
Mid-philtrum	13
Upper lip	11.5
Lower lip	11.8
Lip chin fold	12
Mental eminence	11.5
Beneath chin	8.0

**Table 2.** Depth markers (in millimeters) on lateral parts for the “Mary-Magdalene” skull.

Frontal eminence	5.0
Supraorbitale	6.5
Orbitale	6.0
Lateral orbit	5.5
Lateral zygomatic	9.0
Inferior malar	15.0
Supra-molar	19.0
Inferior molar	17.0
Mid-mandible	11.9

(54.14 mm), Rhinion > Subspinale = Y (42.16 mm), and then applied the formulas written by Rynn, Wilkinson, and Peters.<sup>27</sup> The piriform aperture of the bony structure gave us the inferior and superior limits of the nostrils.<sup>27</sup> Width of the nose was given by applying a 1.65 factor to the maximum nasal aperture.<sup>27</sup> Modiolus was located on a radiant axis spreading out of the canine/premolar contact.<sup>25,27</sup> Lip thickness was given by the “upper” and “lower” lip depth markers and vermillion of the superior lip was estimated on a “small-sized teeth” hypothesis.<sup>27–29</sup> A standard 3D skin was placed on top of the markers and nose/mouth structure and sculpted inside ZBrush 3D package (Pixologic, Inc.). The sculpting process was done at a pore and wrinkles level estimating a skin condition for a woman in the age group of 45 to 50.

Computer-automated reconstructions are not taken into account in this study because they only produce general volumetrics without entering in details. They also need the whole skull to generate a head volume. The purpose of this reconstruction was to create a lifelike portrait based on the facial bones of the skull extracted by photogrammetry.

**Figure 4.** Binocular lenses examination of one hair showing distribution of the melanin within the medulla (×40 magnification).

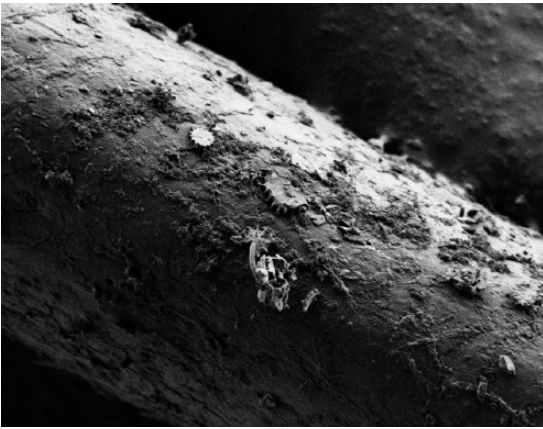
Forensic facial reconstructions result in portraits, which means that some subjective decisions have to be made: angle of camera, framing, lighting, facial expression, and tilting of the head. Those decisions were made with an ethical purpose and an attempt to give a neutral expression of serenity to the face. Eyebrows, eyelids, and hair were hand-created and sculpted in 3D, according to the hair fibers study that was done by the scientific team that concluded the fibers color had a range from dark brown to black. Rendering of the human skin was done with VrayforC4D software (LaubLab Wien, Vienna, Austria) which calculates the refraction of light in the deep skin according to the ambient light source. We chose a soft key one light scheme that could remember an interior setup. The pictures are constituted of 2.073.600 pixels each and require 30 minutes of rendering on an Apple Mac Pro (Apple, Cupertino, CA, USA) with 32 GB RAM and 12 cores at 2.66 Ghz.

## Results

Classical anthropological methods conducted from the 3D photogrammetry of the skull surface confirmed the data from the 1974 scientific examination<sup>5</sup>: morphologic facial characteristics were compatible with a female origin (round and large orbits with sharp upper margins, small brow ridge and vertical forehead, smooth muscular surfaces, large and rounded frontal eminence).<sup>30</sup> From a medical point of view, no pathologic lesion was visible on the whole accessible anatomical zones, ie, no trauma, no infection, etc. No trace of embalming and no cause of death were identified.

Microscopic examination (both optical, SEM and HIM) of hair showed a global thickness of 80 μm (from 76 to 92 μm, depending from the samples), with no evidence of any parasite (especially no lice); melanin concentration and aspect of melanosomes confirmed a dark brown and focally red natural hair color (Figure 4) and showed significant superficial diatomaceous deposits (Figure 5).<sup>31</sup> One type of diatom (probably monospecific), which is highly fragmented and corroded, was identified as aff. *Tertiarius transilvanicus* var. *disseminatopunctatus* (Pantocsek), a fossil species (Tertiary era) compatible with

the use of clay deposited on the hair as a prevention method against lice, or as a dye.<sup>32,33</sup> It is also not possible to exclude the possibility of an ancient contamination of the hair during the



**Figure 5.** Scanning electron microscopic aspect of one hair with one of the numerous diatoms embedded at the surface ( $\times 1000$  magnification).

burial of the human remains, but this hypothesis appears unreliable because of the direct environment of the corpse and the nonclayey nature of the site.

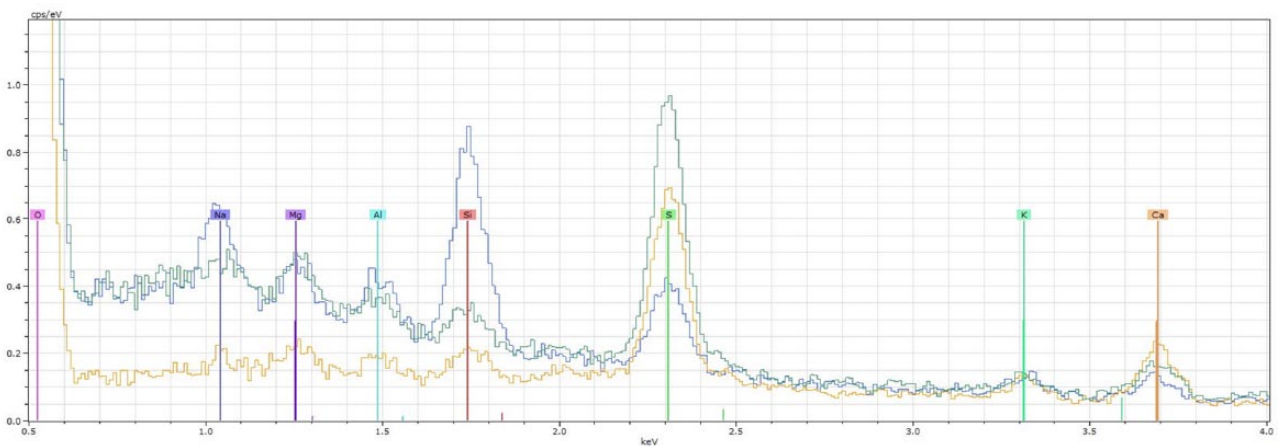
Elemental analysis of the most superficial layer of the hair put to light a composition made of a mix between hair in itself (biological tissue) and clay (Figure 6): carbon (C), oxygen (O), sodium (Na), magnesium (Mg), Aluminum (Al), Silica (Si), Sulfur (S), Potassium (K), and Calcium (Ca). No toxicologic component was found at the level of the surface.

The facial reconstruction's successive steps are presented in Figures 7 to 10.

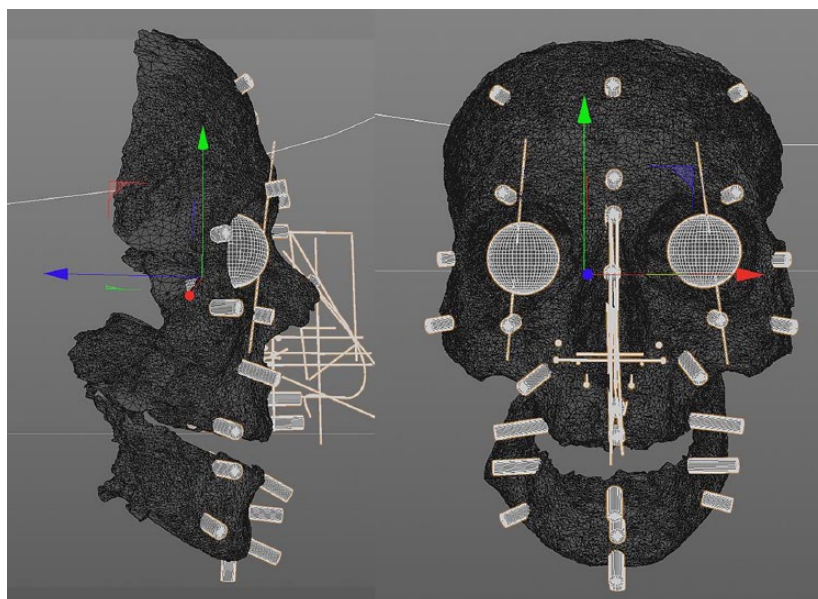
### Conclusions

This study shows again the importance of interdisciplinarity and the convergent contributions of the various disciplines mobilized for the reconstruction of the history of an individual from its material testimonies.


Subsequent analyses will be required to progress in accurately identifying this relic, beginning with carbon-dating and



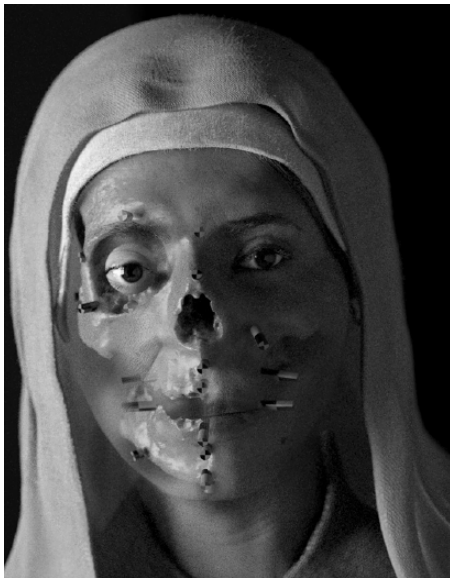**Figure 6.** Elemental analysis of the most superficial layer of one hair with energy-dispersive X-ray.




**Figure 7.** Soft tissues depth markers on the skull.



**Figure 8.** Soft tissues depth markers and muscles on the skull.



**Figure 9.** Soft tissues depth markers under the skin.



**Figure 10.** Facial reconstruction of the face of "Mary-Magdalene."

DNA extraction to confirm sex and get a more precise identification of the ethnic/geographic origin of the individual.

In any case, this preliminary study is important in demonstrating that medico-surgical techniques applied to ancient human remains make it possible to transform them from the status of a single object to that of a patient, restoring their relative biological reality in an objective way.

### Acknowledgements

The authors thank Lionel Aupart for technical support and father Florian Racine for constant help and total access to the remains.

### Author Contributions

PC directed the study, did the microscopic analyses, and wrote major part of the manuscript. PF performed the facial reconstruction. SoM and FS did the diatom analyses. AA did part of the skull photograph coverage. YU directed the photogrammetry process. RW carried out the SEM and surface elemental analyses. StM enhanced the historical context. NB and all other co-authors had critical input on the whole manuscript.

### ORCID iD

Philippe Charlier  <https://orcid.org/0000-0003-0357-511X>

### REFERENCES

1. Saxer V. *Le culte de Marie-Madeleine en Occident des origines à la fin du moyen âge*. Paris, France: Clavreuil; 1959.
2. Trouillet MC. *Les reliques de sainte Marie-Madeleine*. Onet-le-Château, France: Editions Petrus; 2016.
3. Franzoni A. *Sainte Marie-Madeleine et les saints de Provence dans la tradition provençale*. Plan-d'Aups-Sainte-Baume, France: Éditions ASTSP; 2015–2016.
4. Jean Gobi l'Ancien SJ. *Miracles de sainte Marie-Madeleine*. Paris, France: CNRS Éditions; 1996.
5. Boyer R, Arnaud G, Arnaud S. *Les ossements dits de Marie-Madeleine (Étude anthropologique)*. Marseille, France: CNRS, Institut d'Archéologie Méditerranéenne, Aix-Marseille University; 1974.
6. [http://www.ciceromoraes.com.br/doc/pt\\_br/Moraes/Maria\\_Madalena.html](http://www.ciceromoraes.com.br/doc/pt_br/Moraes/Maria_Madalena.html). Accessed November 20, 2018.

7. Miranda GE, Wilkinson CM, Roughley M, Beaini TL, Melani RFH. Assessment of accuracy and recognition of three-dimensional computerized forensic craniofacial reconstruction. *PLoS ONE*. 2018;13:e0196770.
8. Zednikova MP, Velemínska J. Eyeball position in facial approximation: accuracy of methods for predicting globe positioning in lateral view. *J Forensic Sci*. 2018;63:221–226.
9. Bulut O, Jessica Liu CY, Koca F, Wilkinson CM. Comparison of three-dimensional facial morphology between upright and supine positions employing three-dimensional scanner from live subjects. *Leg Med (Tokyo)*. 2017;27:32–37.
10. Herrera LM, Strapasson RAP, Zanin AA, da Silva JVL, Melani RFH. Comparison among manual facial approximations conducted by two methodological approaches of face prediction. *J Forensic Sci*. 2017;62:1279–1285.
11. Parks CL, Kyllonen KM, Monson KL. Application of enhanced point estimators to a sample of in vivo CT-derived facial soft tissue thicknesses. *J Forensic Sci*. 2017;62:994–997.
12. Strapasson RAP, Herrera LM, Melani RFH. Forensic facial reconstruction: relationship between the alar cartilage and piriform aperture. *J Forensic Sci*. 2017;62:1460–1465.
13. Zednikova MP, Velemínska J. Vertical lip position and thickness in facial reconstruction: a validation of commonly used methods for predicting the position and size of lips. *J Forensic Sci*. 2016;61:1046–1054.
14. Dias PE, Miranda GE, Beaini TL, Melani RF. Practical application of anatomy of the oral cavity in forensic facial reconstruction. *PLoS ONE*. 2016;11:e0162732.
15. Lee WJ, Wilkinson CM, Hwang HS, Lee SM. Correlation between average tissue depth data and quantitative accuracy of forensic craniofacial reconstructions measured by geometric surface comparison method. *J Forensic Sci*. 2015;60:572–580.
16. Stephan CN, Munn L, Caple J. Facial soft tissue thicknesses: noise, signal, and P. *Forensic Sci Int*. 2015;257:114–122.
17. Hussein E, Al Khateeb S, Watted N, Aksoy A, Acar A, Abu Mowais M. Evaluation of facial soft tissue parameters for Palestinians using Holdaway analysis. *Saudi Dent J*. 2011;23:191–195.
18. Wilkinson CM. European facial tissue measurements (modified from Helmer, 1984). In: Wilkinson CM, ed. *Forensic Facial Reconstruction*. Cambridge: Cambridge University Press; 2004.
19. Bekerman I, Gottlieb P, Vaiman M. Variations in eyeball diameters of the healthy adults. *J Ophthalmol*. 2014;5:503645.
20. Krogman WM. *The Human Skeleton in Forensic Medicine*. Springfield, MA: Charles C Thomas; 1962.
21. Wilkinson CM, Mautner SA. Measurement of eyeball protrusion and its application in facial reconstruction. *J Forensic Sci*. 2003;48:1–5.
22. Whitnall E. *Anatomy of the Eye and Orbit*. Oxford, England: Oxford Medical Publications; 1921.
23. Balueva TS, Veselovskaya EV. New developments in facial reconstruction. *Archaeol Ethnol Anthropol Eurasia*. 2004;4:143–152.
24. Gerasimov MM. *The Face Finder*. New York, NY: Lippincott; 1971.
25. Gerasimov MM. *The Reconstruction of the Face From the Basic Structure of the Skull*. GPD: Moscow, Russia; 1955.
26. Rynn C, Wilkinson CM. Appraisal of traditional and recently proposed relationships between the hard and soft dimensions of the nose in profile. *Am J Phys Anthropol*. 2006;130:364–373.
27. Rynn C, Wilkinson CM, Peters HL. Prediction of nasal morphology from the skull. *Forensic Sci Med Pathol*. 2010;6:20–34.
28. Gatliff BP. Facial sculpture on the skull for identification. *Am J Forensic Med Pathol*. 1984;5:327–332.
29. Angel JL. *Restoration of Face and Head for Identification*. St. Louis, MO: SLU; 1978.
30. Buikstra JE, Ubelaker DH. *Standards for Data Collection From Human Skeletal Remains* (Archaeological Survey Research Series No. 44). Fayetteville, AR; 1994.
31. Charlier P, Weil R, Deblock R, Augias A, Deo S. Helium ion microscopy (HIM): proof of the applicability on altered human remains (hairs of Holy Maria-Magdalena). *Leg Med (Tokyo)*. 2017;24:84–85.
32. Håkansson H, Khursevich G. *Tertiarus* gen. nov., a new genus in the Bacillariophyceae, the transfer of some cyclotelloid species and a comparison to closely related genera. *Diat Res* 1997;12:19–33.
33. Houk V, Klee R, Tanaka H. Atlas of freshwater centric diatoms with a brief key and descriptions. Part III: Stephanodiscaceae A, Cyclotella, Tertiarus, Discostella. *Fottea* 2010;10.